

Brief Reports

SUCCESSFUL MANAGEMENT OF INTRUDED HYDROGEL BUCKLE WITH BUCKLE REMOVAL, SCLERAL PATCH GRAFT, AND VITRECTOMY

GREGG T. KOKAME, MD,
GREGORY G. GERMAR, MD

From the Division of Ophthalmology, Department of Surgery, University of Hawaii School of Medicine, Honolulu, Hawaii; and The Retina Center at Pali Momi, Kapi'olani Health, Aiea, Hawaii.

Hydrogel implants used for scleral buckling in retinal detachment surgery have been reported to develop swelling many years after the initial surgery.¹⁻³ Secondary complications, including chronic discharge and granuloma formation,³ extrusion of the implant through the conjunctiva,^{2,3} double vision and restriction of ocular motility,² and intrusion of the implant through the sclera,¹ may develop secondary to progressive buckle swelling. Intrusion of the buckle through the sclera into the subretinal space is a particularly difficult management problem and can result in severe vision loss, recurrent retinal detachment, and subretinal or vitreous hemorrhage.^{1,4} In the five cases of hydrogel buckle intrusion with loss of vision reported by Marin and colleagues,¹ none of the patients recovered useful vision in the eye with or without surgical intervention. We report the successful surgical management of intrusion of a hydrogel buckle into the subretinal space resulting in a full-thickness scleral defect.

Case Report

A 57-year-old woman had a 2-week history of a sudden onset of blurred vision and metamorphopsia in her right eye. Eleven years earlier, she underwent a scleral buckling procedure at another institution for a retinal detachment in the same eye. On examination, her best-corrected visual acuity was 20/70 in the right eye

The authors do not have a proprietary interest.

Reprint requests: Gregg T. Kokame, MD, The Retina Center at Pali Momi, 98-1079 Moanalua Road, Suite 470, Aiea, HI 96701.

(−7.75 sphere) and 20/25 in the left eye (−4.25 sphere). Intraocular pressure was 14 mmHg in the right eye and 13 mmHg in the left eye. Slit-lamp examination of both eyes revealed 1+ nuclear sclerotic cataract, and the right eye showed no evidence of conjunctival injection or external buckle exposure. Fundus examination showed an attached retina with an extremely high superotemporal buckle effect extending posterior to the superotemporal arcade from the 10- to 12-o'clock positions (Figure 1). The buckle element itself was visualized under the RPE, having eroded through the scleral bed.

Review of the operative report of the initial retinal detachment surgery showed that a MIRAgel meridional implant No. 907 (MIRA, Inc., Uxbridge, MA) was used for localized support under a No. 280 circumferential solid silicone tire. These buckle elements had been placed into a partial-thickness dissected scleral bed and under scleral flaps.

Because the intruded buckle resulted in acute symptomatic vision loss and was encroaching over the central macula, buckle removal was recommended with a poor visual prognosis. The swollen hydrogel implant was restricted from outward expansion by an overlying circumferential tire, and the underlying sclera was thinned by scleral dissection.

An external approach was planned for buckle removal with vitrectomy for secondary complications and a scleral graft available to patch any visible scleral defect. The scleral flaps were dissected off of the encircling tire, and the tire was removed in the superotemporal quadrant. The hydrogel sponge had intruded completely through the scleral bed into the eye. Because the buckle was extremely friable, it was removed by grasping the hydrogel buckle with a cryoprobe with a gentle side-to-side motion, while supporting the underside of the hydrogel buckle with a lens loupe to prevent further intrusion. The buckle element was removed intact and was noted to be much larger (approximately 11 × 11 × 5 mm) than its original size (7.5 × 5.5 mm). The eye became hypotonous with vitreous loss and an open scleral defect. Due to the risk of extrusion of the retina through the large scleral defect, no infusion was placed into the vitreous cavity. The posteriorly located scleral defect was repaired using a 1 × 1 cm scleral patch graft (Tutoplast, Innovative Ophthalmic Products, Inc., Costa Mesa, CA) with a watertight closure using interrupted 8-0 nylon sutures. Once the scleral graft was in position, the eye was reformed with a pars plana injection of balanced salt solution. A vitrectomy was then performed, and the retina was noted to have redetached with the only tears being the original tear supported by the radial buckle and the full-thickness scleral and retinal defect within the bed of the buckle. Repair of the retinal detachment was performed using perfluorooctane liquid, endolaser around the previous site of the removed radial buckle with the full-thickness defect, and silicone oil placement under low pressure. The patient felt that she could not maintain face-down positioning and chose silicone oil over the alternative of intraocular gas.

RETINA,™ The Journal of Retinal and Vitreous Diseases, encourages authors to submit **Brief Reports** describing unusual findings, new techniques, and new instruments. Material submitted for consideration in this section of the journal is done so with the assumption that the data provided do not duplicate previously published material and that the material has not been submitted for consideration elsewhere. Each author must sign a disclosure to this effect (see Instructions to Authors for complete wording of transfer letter). Brief Reports submitted for this section of the journal may be subjected to the standard review process that is applied to other material submitted to **RETINA**. Brief Reports should follow the requirements listed in the Instructions to Authors, with the following caveats: Brief Reports should not exceed 4 pages in length; no more than 5 references should be cited; and each Brief Report should include no more than 4 figures.

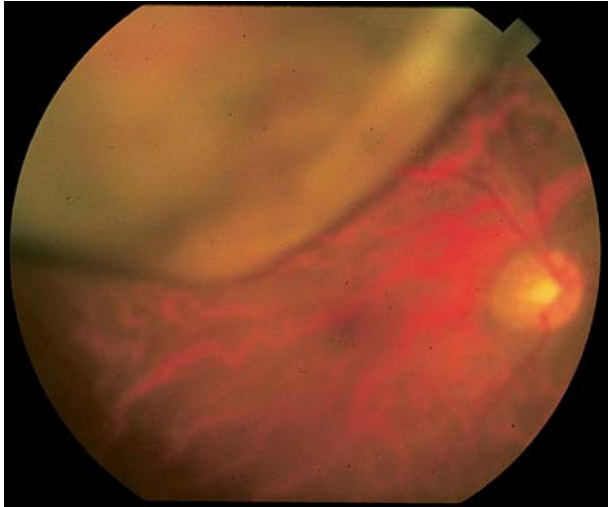


Fig. 1. Fundus photograph showing the preoperative appearance of an intruded superotemporal buckle. Note the markedly high buckling effect encroaching over the macula. The patient had an acute vision loss for 2 weeks.

Postoperatively, the retina remained attached with a best-corrected visual acuity of 20/400 through silicone oil. Three months later, a posterior subcapsular cataract developed. Pars plana lensectomy was performed leaving the anterior capsule intact for future IOL support, combined with pars plana vitrectomy and silicone oil removal. Additional endolaser treatment was added around the edges of the scleral graft to minimize the risk of redetachment. One month postoperatively, the best-corrected visual acuity was 20/40 (+5.75 sphere). Following secondary posterior chamber IOL implantation into the sulcus, visual acuity improved to 20/25 ($-1.25 + 0.50 \times 82$); the intact anterior capsule remained clear; and the retina remained attached 1 year following buckle removal (Figure 2).

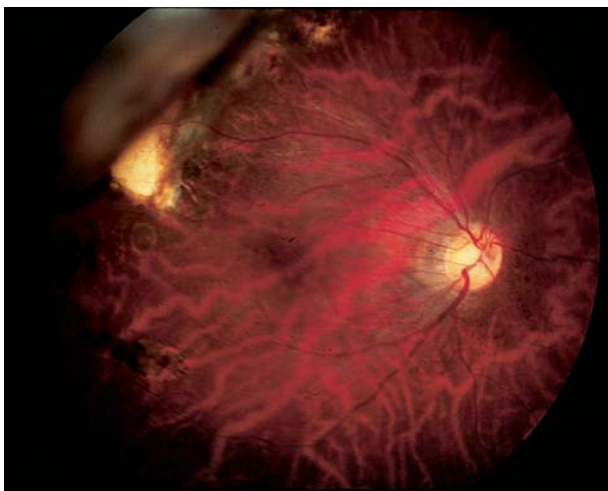

Fig. 2. Fundus photograph showing the postoperative appearance. Note the markedly reduced buckling effect and the superotemporal, white, scleral patch graft. Vision recovered to 20/25.

Discussion

Hydrogel implants were initially thought to be good buckling elements, because of an effective buckling effect, the softness and elasticity of the original material, their lack of dead spaces possibly decreasing the risk of infection, their hydrophilic characteristics allowing absorption of antibiotic, and the stimulation of a fibrous capsule.⁵ However, late complications have been reported to develop due to progressive implant swelling. Marin et al¹ reported seven cases in which long-term complications developed from swelling of the MAI hydrogel intrascleral buckling implant 7 to 10.5 years after placement. Laboratory evaluation confirmed chemical changes within the polymer of the implant, which changed from a soft, spongy, whitish material to a friable, gellike, cream-colored material. The most severe complications were buckle intrusion, which occurred when supplemental hydrogel buckle elements were used under a solid silicone implant in a dissected scleral bed, similar to this reported case. All five patients with symptomatic vision loss and buckle intrusion had persistent poor vision with either observation or surgical attempts at repair, including cutting of the encircling band, buckle removal without vitrectomy, and vitrectomy with removal of the intruded implant from the vitreous. Hwang and Lim² reported a case of scleral buckle extrusion, swelling, and fragmentation associated with a MIRAgel episcleral explant. MIRAgel has the same chemical composition as MAI hydrogel buckles. Roldan-Pallares and colleagues³ recommended periodic long-term follow-up for hydrogel implants because of long-term alterations in their chemical composition and eventual swelling, which resulted in late extrusion and discharge 7 to 10 years after placement.

The intrusion of buckle elements into the eye through the sclera results in subretinal and vitreous hemorrhages, recurrent retinal detachment, intrusion through the retina, possible complete loss of vision, and phthisis. Because of difficulty in management of this complication and the high risk of surgical intervention, observation has often been recommended.^{1,4} In this case and others with a hydrogel implant progressively swelling under an overlying tire and intruding through a thin scleral bed, surgical intervention is recommended. With successful removal of the swollen intruded implant, repair of the scleral defect using a scleral graft, and successful vitrectomy repair of the retinal detachment, this case demonstrates potential excellent vision recovery following visual rehabilitation after management of this difficult complication.

References

1. Marin JF, Tolentino FI, Refojo MF, Schepens CL. Long-term complications of the MAI hydrogel intrascleral buckling implant. *Arch Ophthalmol* 1992;110:86–88.
2. Hwang KI, Lim JI. Hydrogel exoplant fragmentation 10 years after scleral buckling surgery. *Arch Ophthalmol* 1997;115:1205–1206.
3. Roldan-Pallares M, del Castillo Sanz JL, Awad-El Susi S, Refojo MF. Long-term complications of silicone and hydrogel explants in retinal reattachment surgery. *Arch Ophthalmol* 1999;117:197–201.
4. Shami MJ, Abdul-Rahim AS. Intrusion of a scleral buckle: a late complication of retinal reattachment surgery. *Retina* 2001;21:195–197.
5. Ho PC, Chan IM, Refojo MF, Tolentino FI. The MAI hydrophilic implant for scleral buckling: a review. *Ophthalmic Surg* 1984;15:511–515.

INDOCYANINE-GREEN ANGIOGRAPHY IN ACUTE IDIOPATHIC EXUDATIVE POLYMORPHOUS VITELLIFORM MACULOPATHY

RAUL N.G. VIANNA, MD,
ACÁCIO MURALHA, MD,
LÍLIA MURALHA, MD

From the Department of Ophthalmology, Fluminense Federal University, Niterói, Rio de Janeiro, Brazil.

In 1988 Gass and coworkers¹ described two patients reporting headache and acute vision loss and having a fundus picture of multiple, round, yellow–white subretinal lesions at the level of the retinal pigment epithelium (RPE), associated with serous detachment in both eyes. As the authors could not find a causative agent for the disease, they termed it acute idiopathic exudative polymorphous vitelliform maculopathy (AIEPVM).^{1,2} After some weeks of receiving systemic corticosteroids, these patients recovered full vision, but while receiving the treatment, the lesions evolved to large, polymorphous, yellow subretinal deposits similar to that seen in patients with Best disease. In 1997 Gass reported a third patient with AIEPVM who recovered vision without medication, but the status of the fundus could not be determined because the patient refused further follow-up.²

In this report, we present a patient with AIEPVM who recovered full visual acuity without treatment and developed few fundus abnormalities after 8 months of follow-up. The indocyanine green angiographic findings of AIEPVM are also described.

Reprint requests: Raul N.G. Vianna, MD, Av. Ari Parreiras, 438, Icarai, Niterói, RJ, Brazil CEP: 24230-322.

Case Report

A 52-year-old previously healthy woman had a headache and acute loss of vision in both eyes of 3 days' duration. Her corrected visual acuity was 20/80 in both eyes. Slit-lamp examination of the anterior segments was unremarkable. Intraocular tension was within normal limits in both eyes. Numerous pale, round, oval, yellow–white lesions at the level of the RPE were seen in both fundi and were located particularly near the superior vascular arcades; a small, yellow lesion was observed in both foveal regions. A curvilinear, yellow subretinal deposit following the course of the inferior vessels was also observed bilaterally (Figure 1). The optic disks and retinal vessels appeared normal.

The Arden ratio (electrooculography, slow oscillations) was 1.52 in the right eye and 1.8 in the left eye (normal value, ≥ 1.8) The electroretinogram, recorded in accordance with the International Society of Clinical Electrophysiology of Vision standards, was normal and symmetric.

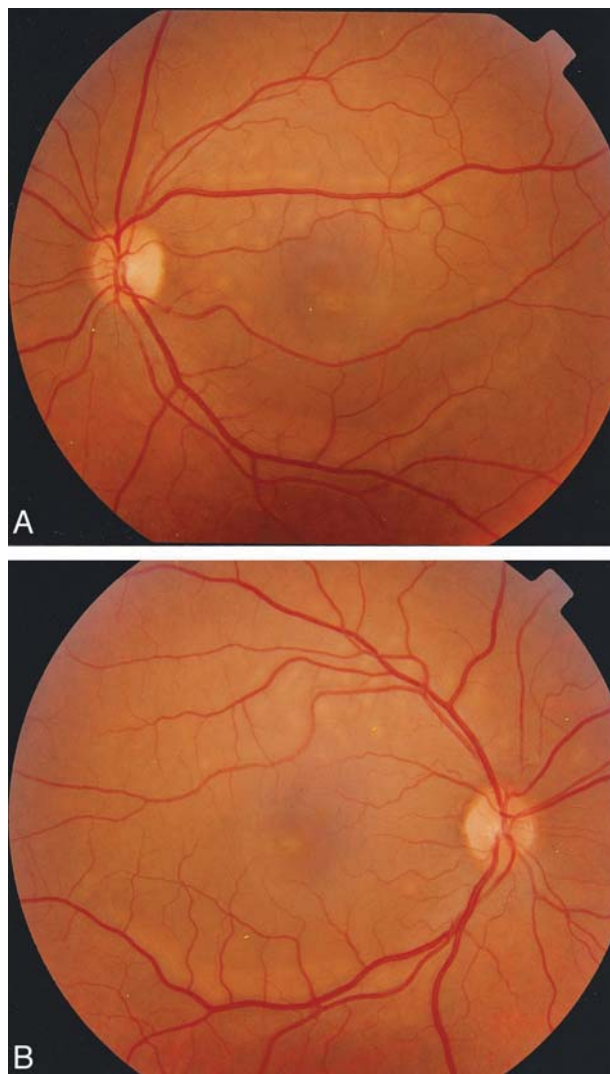


Fig. 1. A, B, Color photograph of both fundi showing numerous pale, round, yellow–white lesions at the level of the retinal pigment epithelium. A curvilinear, subretinal, yellow-white deposit is also observed following the inferior vascular arcades.