

# *Diagnostic and Therapeutic Challenges* \_\_\_\_\_ Edited by H. Richard McDonald

Submitted by Lucy H.Y. Young; Commented by Jeffrey G. Gross, James C. Lai and Jeffrey L. Shakin, and John T. Thompson

This case was submitted by Dr. Lucy H.Y. Young of the Massachusetts Eye and Ear Infirmary, Boston, Massachusetts, for the Diagnostic and Therapeutic Challenges Section of RETINA.

## Case Report

A 23-year-old healthy white graduate student was referred to our clinic because of decreased vision, left eye worse than right, for the last 4 months. Two years earlier, the patient was seen by the referring physician and was diagnosed with choroidal folds bilaterally associated with short axial length (18.5 mm bilaterally). Visual acuity was 20/25 bilaterally then. On our examination, visual acuity with correction was 20/40-2 in the right eye and 20/100 in the left. External examination showed a proportionately petite man (4'11" tall) accompanied by parents who were taller (5'5" tall mother and 5'11" father). Intraocular pressures were measured to be 17 mmHg in the right eye and 18 mmHg in the left. Anterior segment examination was unremarkable. Fundus examination showed crowded optic nerves and multiple chorioretinal folds through the macula with a component of epiretinal membrane bilaterally (Figure 1). In addition, pigment clumpings at the retinal pigment epithelium (RPE) level with shallow serous detachment of the macula were present, left worse than right. Fluorescein angiography showed macular RPE disturbance with epiretinal membrane and serous detachment, left > right (Figure 1). B-scan revealed diffuse choroidal thickening and elevated optic nerve and macula bilaterally (Figure 2). OCT evaluation showed irregular inner retinal surface, reflective RPE changes, and subretinal fluid, left > right (Figure 3). The patient denied any dental or skin abnormalities.

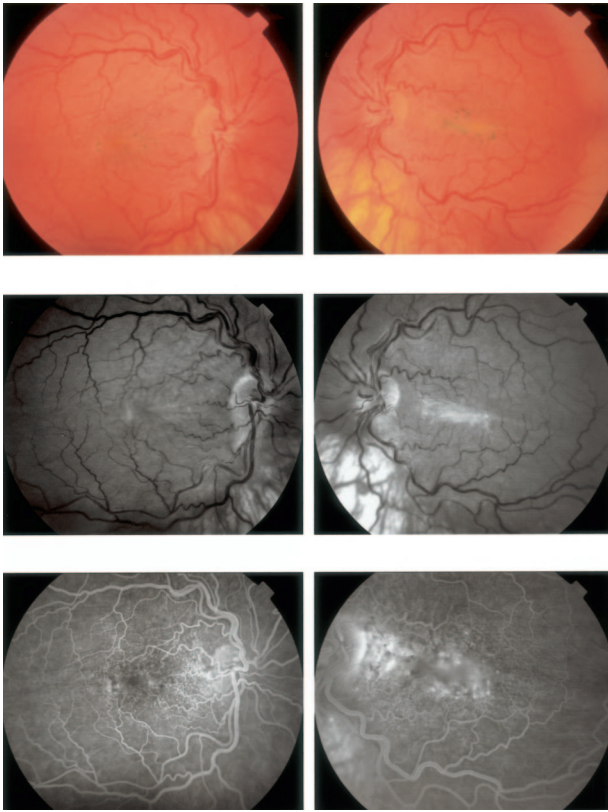
We asked several experts for their opinion.

**Dr. Jeffrey G. Gross (Columbia, SC):** \_\_\_\_\_

Dr. Young describes a 23-year-old white man with a 4-month history of decreased vision in both eyes. He

was evaluated 2 years earlier by another physician. His visual acuity at that time was 20/25 in both eyes attributed to bilateral choroidal folds associated with short axial length (18.5 mm in each eye). On examination his visual acuity is 20/40<sup>-2</sup> right eye and 20/100 left eye. The refraction is not provided but assumed to be hyperopic (although emmetropia and even myopia may occur with short axial lengths). Physical examination disclosed a stature described as proportionately petite. His height was 4'11" and he was accompanied by parents of normal stature. Intraocular pressures and anterior segment examination were normal.

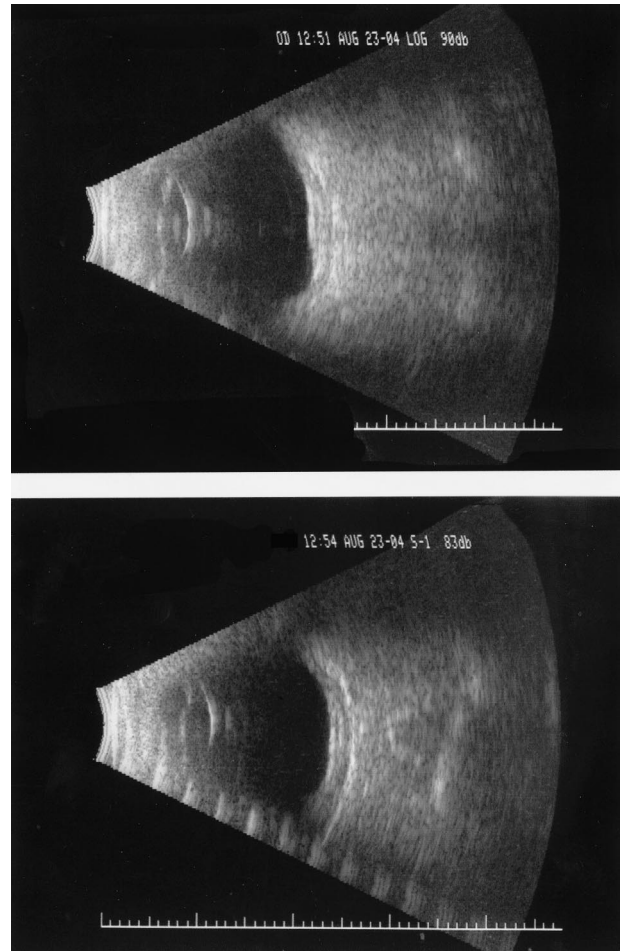
The fundus photograph of both eyes shows crowded optic nerves with no visible cupping. The major retinal vessels are mildly tortuous. The macula has clumps of RPE associated with chorioretinal folds. Although an epiretinal membrane is described by the author it is not clearly seen in the photographs and there is no straightening of the perimacular vessels that are typically seen with a significant epiretinal membrane. There is a horizontal macular abnormality that may represent a fold greater in the left eye. Fluorescein angiography reveals punctate disturbance of the RPE in the papillomacular retina in the mid-phase of the right eye. There is leakage noted in the papillomacular retina and central macula with pooling of dye surrounded by a mild disturbance of the RPE in the late phase of the left eye. The B-scan ultrasound images show a small globe with choroidal thickening best imaged with the gain reduced as noted in the left eye. There is a normal posterior echo from the crys-



**Fig. 1.** Fundus photograph. Note chorioretinal folds and epiretinal membrane in addition to shallow serous detachment with pigment clumpings. Fluorescein angiography showed diffuse retinal pigment epithelium disturbance with multiple leakage sites, left > right.

talline lens and the vitreous is clear. There is no retinal or choroidal detachment. OCT images reveal in the right eye a significant distortion of the inner retina possibly associated with a thin epiretinal membrane, tiny amount of subretinal fluid, and possibly a tiny RPE clump. The left eye shows distortion and irregularity of the inner retina, subretinal fluid, and attenuation or shadowing of the RPE layer.

The most important piece of information is the axial length. Microphthalmos can occur in different forms. Simple microphthalmia is an eye that is normal except for a short total axial length. Complex microphthalmos is associated with either anterior or posterior malformations. A rare form of microphthalmos is posterior microphthalmos, which is associated with papillomacular folds, absence of the capillary free zone, and hyperopia. This form of microphthalmos disproportionately affects the posterior segment with a normal external appearance of the eye.<sup>1</sup> Nanophthalmos refers to a bilateral condition in which the eye is less than 19 mm in length with extremely thick sclera, a normal or slightly thicker crystalline lens, and severe hyperopia. Nanophthalmos may be associated with uveal effusions and congested choroid that may begin



**Fig. 2.** B-scan ultrasounds show diffuse choroidal thickening and macular elevation bilaterally (top, right; bottom, left).

in the macula. This is demonstrated by the B-scan ultrasound images of this patient. As a consequence of increased resistance to venous outflow by the vortex veins as a result of the thick sclera a progressive congestion of the choroid usually occurs in the third to fifth decade of life. Initially there may be retinal folds in the macula with decreased vision eventually leading to a chronic effusion resulting in a nonrhegmatogenous retinal detachment.

Although the fluorescein angiogram is usually normal in nanophthalmos there can be a leopard-spot appearance of the RPE as a result of uveal effusions. In posterior microphthalmos an absence of the capillary free zone may occur. The findings demonstrated in this patient have certain findings seen in atypical and chronic idiopathic central serous chorioretinopathy (ICSC). Typically these bilateral findings include multiple leaks and a mottled appearance of the RPE. The fluorescein angiogram of this patient showing punctate leakage and pooling and the OCT showing serous detachments are consistent with these findings.

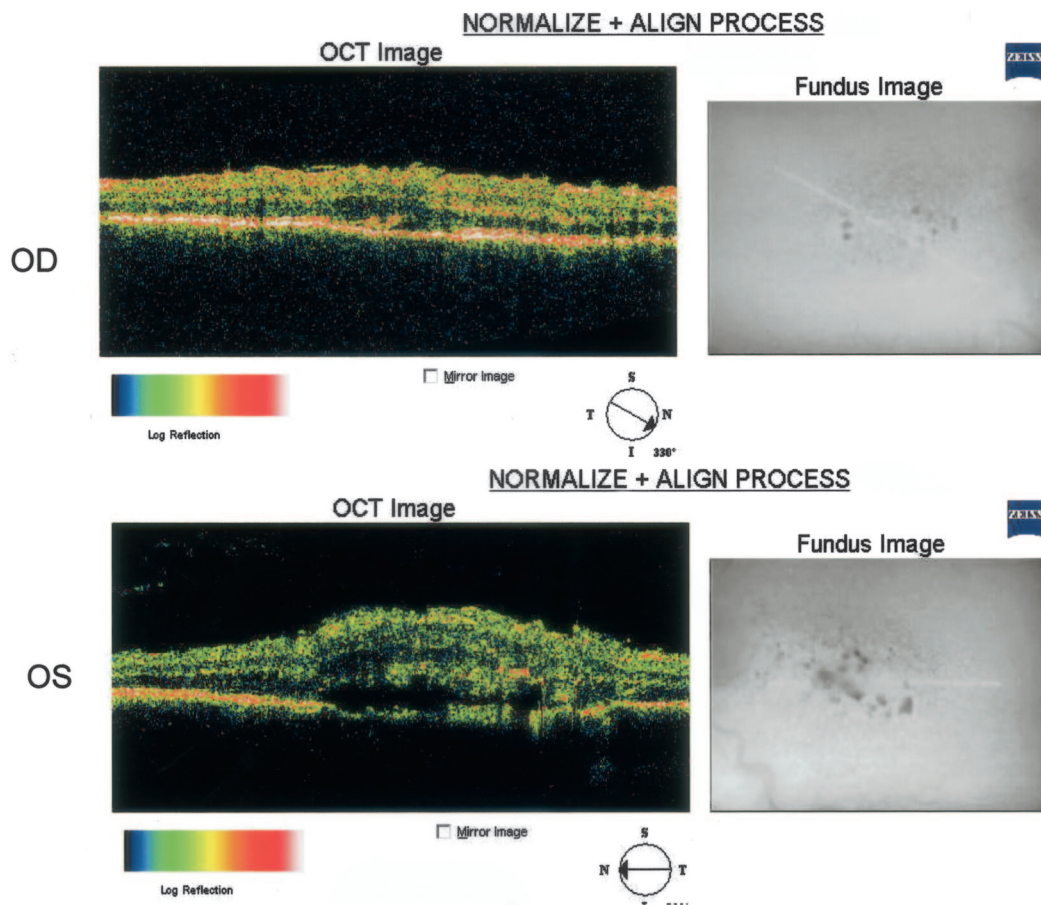


Fig. 3. Optical coherence tomograms show irregular retinal surface, macular thickening, and serous detachments, left > right.

A single case of ICSC with multiple leaks of the choroid resulting in chorioretinal pigment changes has been described with Hallerman-Streiff syndrome. This syndrome includes nanophthalmos and dwarfism.<sup>2</sup> The OCT in the patient presented demonstrates significant irregularity of the inner retina and folds that are consistent with nanophthalmos and there may be a thin ERM seen in the OCT of right eye. It is presumed that the retinal folds result from a redundancy of the retinal layer caused by retarded growth of the scleral and RPE layers. However, we do not see the severe infolding that is more typically seen in posterior microphthalmos.<sup>1</sup>

Nanophthalmos generally is not associated with systemic syndromes although there are three that need to be considered in this patient: Hallermann-Streiff-Francois syndrome, oculodentodigital syndrome, and Kenny-Caffey syndrome.<sup>3,4</sup> Hallermann-Streiff-Francois is associated with birdlike facies, proportional dwarfism, cutaneous atrophy, and dental abnormalities. Oculodentodigital syndrome is also associated with dental abnormalities, as well as syndactyly, but not dwarfism. The patient described denied any dental or skin abnormalities so these two syndromes are

effectively ruled out. Kenny-Caffey syndrome is characterized by 1) nanophthalmos associated with crowded optic nerves or pseudopapilledema, and tortuous blood vessels, 2) medullary stenosis of the long bones, 3) proportional dwarfism, and 4) intermittent to long-standing hypocalcemia due to mild to complete hyperparathyroidism. Typically the patients have normal intelligence.<sup>4,5</sup>

Therefore the patient described may have Kenny-Caffey syndrome associated with nanophthalmos, tortuous retinal vessels, proportional dwarfism, and, since he is a graduate student, normal intelligence. This syndrome occurs either sporadically or by autosomal recessive inheritance. This is consistent with this patient's short stature and normal appearing parents. The fluorescein angiogram demonstrates punctate leakage, however this is not typically seen with nanophthalmos and leakage is not thought to be the cause of the uveal effusions that occur later in life in these small eyes, rather it is a result of increased resistance to venous outflow. ICSC has been reported in the Hallermann-Streiff syndrome but not in Kenny-Caffey syndrome. The two syndromes share similar



features of nanophthalmos and proportional dwarfism so it is reasonable to suggest that this patient may have mild choroidal congestion as a result of the nanophthalmos as well as chronic bilateral ICSC. Kenny-Caffey syndrome can be diagnosed by a radiologic evaluation of the long bones and because of the potentially severe systemic complications an evaluation for hypocalcemia is recommended.

**Drs. James C. Lai and Jeffrey L. Shakin (Great Neck, NY):**

Dr. Young describes a 23-year-old man of short stature who presents with a 4-month history of progressively worsening vision bilaterally. Fundus photographs reveal crowded discs with slightly increased vascular tortuosity. Faint chorioretinal folds with overlying epiretinal membranes and RPE pigmentary changes are present in both macula. Fluorescein angiography demonstrates pinpoint areas of hyperfluorescence with mild late leakage at the level of the RPE and the OCT confirms the presence of subretinal fluid left > right. B-scan ultrasonography reveals a short axial length and diffuse choroidal thickening.

The differential diagnosis of this case centers around conditions that lead to choroidal thickening with the development of chorioretinal folds, serous retinal detachments, and secondary chronic macular changes such as macular pucker and RPE hyperplasia. The fact that this nanophthalmic individual is otherwise healthy, but of short stature as compared to his normal sized parents, also alters the differential. Possible conditions include nanophthalmic uveal effusion syndrome, mucopolysaccharidoses (MPS), Vogt-Koyanagi-Harada (VKH) syndrome, posterior scleritis, sarcoidosis, and less likely, central serous retinopathy (CSR), idiopathic choroidal neovascularization, and venous stasis retinopathy. The short axial length of the patient's eyes would argue against idiopathic uveal effusion syndrome, which occurs in normal-sized eyes.

Nanophthalmos, or pure micropthalmos, is a rare disorder in which the eyes are small (anteroposterior length generally between 15 and 20 mm), but otherwise grossly normal in function. Nanophthalmos may be inherited in a sporadic, autosomal dominant, or autosomal recessive manner and is usually not associated with systemic abnormalities. These patients are often hyperopic and predisposed to angle closure glaucoma because of the propensity of the crystalline lens to be slightly enlarged. Although this patient's refractive status was not discussed, the crowded appearance of his discs would be consistent with that of a hyperope. Nanophthalmic eyes also have abnormally thickened sclera, predisposing them to spontaneous choroidal effusions and secondary serous detachments.<sup>6</sup>

Mucopolysaccharidoses are a group of lysosomal enzyme storage disorders in which the body lacks the ability to degrade glycosaminoglycans. There are different subtypes depending on the actual enzymatic deficiency. The sclera in patients with this disorder is abnormally thickened from deposition of mucopolysaccharides, resulting in impaired uveoscleral flow and decreased venous outflow. Nanophthalmos and choroidal effusions have been reported in patients with MPS IIA and IIB (Hunter's) and MPS VIA and VIB (Maroteaux-Lamy) syndrome.<sup>7</sup> Although this patient is short, he does not exhibit the other typical traits of Hunter's syndrome: coarse facies, skeletal dysplasias, hydrocephalus, or progressive deafness. This patient is also unlikely to have Maroteaux-Lamy syndrome, which is characterized by skeletal, cardiac, and hepatic abnormalities, as well as corneal clouding and optic nerve atrophy.

VKH syndrome, posterior scleritis, and sarcoidosis can all present with choroidal thickening with secondary serous retinal detachments. The presence of vitreous cells is not commented on by Dr. Young, although the anterior segment is noted to be normal. The absence of accompanying neurologic symptoms, cutaneous findings, and anterior segment inflammation would argue against VKH, particularly in a white patient. The bilateral nature of disease, and the absence of ocular pain, fluorescein disk leakage, and classic "T" sign on ultrasonography make posterior scleritis less likely. Finally, this patient lacks the intraocular inflammation, iris nodules, or subretinal granulomas that would raise the suspicion for sarcoid.

Central serous retinopathy can sometimes present with a fluorescein pattern that is similar to this case. In fact, when Gass first described the uveal effusion syndrome, he reported a patient who was initially misdiagnosed as having CSR.<sup>8</sup> However, findings in this case that argue against CSR are the presence of nanophthalmos and choroidal thickening. The absence of subretinal hemorrhages and the presence of bilateral disease with choroidal thickening also make idiopathic choroidal neovascularization unlikely in this patient.

Finally, one must consider conditions that can lead to increased vascular tortuosity, although they are certainly much lower on the differential. There is no evidence of dilated conjunctival veins, chemosis, or pulsating exophthalmos to suggest a carotid cavernous fistula. Coarctation of the aorta is also unlikely because it is usually picked up at a younger age, and the tortuosity of the retinal arterioles is more dramatic. Hematologic conditions such as increased blood viscosity could result in increased venous tortuosity. However, the nanophthalmos with choroidal thickening suggests that the increased vascular tortuosity is a

result of a mechanical inhibition to venous outflow, rather than an underlying hematologic abnormality.

Additional workup at this time would start with a careful family history, concentrating on any history of inherited diseases. The diagnosis of mucopolysaccharidoses can be made by the detection of the enzymatic deficiency or by elevated levels of urinary glycosaminoglycans. Because patients with mucopolysaccharidoses can often have fatal cardiac abnormalities, a complete cardiac workup would be important. It would also be reasonable to consider a very limited uveitis and coagulopathy workup by obtaining a chest x-ray, complete blood count, and basic metabolic panel. Testing for ANA, ANCA, rheumatoid factor, homocysteine, protein C and S activity, antiphospholipid antibodies, and anticardiolipin antibodies would only be warranted if there was a positive review of systems or family history to suggest any thrombophilia.

The management goals in this patient would be directed primarily at addressing the serous retinal detachments. Systemic steroids have been used with mixed success in uveal effusion syndromes. However, patients often require posterior sclerectomies with or without vortex vein decompression to control the effusions and retinal detachments. Once the serous retinal detachments have resolved, removal of any symptomatic macular pucker could be considered.

**Dr. John T. Thompson (Baltimore, MD):** \_\_\_\_\_

Dr. Young's patient presents an interesting differential of ocular and systemic disorders that could cause chorioretinal folds. The patient does appear to have chorioretinal folds rather than retinal folds, although the presence of bilateral epiretinal membranes should raise consideration of retinal folds alone. The presence of an epiretinal membrane is uncommon in eyes with chorioretinal folds and could be secondary to chronic serous detachments. The ultrasound shows one typical feature of chorioretinal folds where the posterior curvature of the globe is flattened.<sup>9</sup> The OCT shows typical features of chorioretinal folds in the outer retina with a serous detachment in addition to an epiretinal membrane causing wrinkling of the inner retina. The fluorescein angiogram does not show the typical alternating hyper- and hyperfluorescent bands from chorioretinal folds, but these may not be prominent in all eyes.

The most likely etiology of the chorioretinal folds is the patient's hyperopia. Hyperopia is often associated with bilateral chorioretinal folds<sup>10</sup> and eyes with very short axial lengths (18.5 mm bilaterally) have a greater likelihood of choroidal folds. Males with hyperopia seem more prone than females to develop chorioretinal folds for unknown reasons.<sup>11</sup> A number

of other possible diagnoses should be considered, but most can be eliminated with additional testing. An MRI scan of the orbit with contrast to rule out orbital masses or thyroid disease is indicated, but unlikely to uncover undiagnosed pathology. Thyroid function tests should be done to look for hyperthyroidism even if the MRI is negative for extraocular muscle enlargement. The MRI will also help to rule out posterior scleritis or orbital inflammation, which does not appear to be present by clinical examination, and to make certain the reduced axial lengths are not secondary to orbital masses. It is still possible the patient had previous posterior scleritis in the past since chorioretinal folds may persist after resolution of the inflammation. Disk edema from pseudotumor cerebri may be associated with chorioretinal folds,<sup>12</sup> but the disk shows no definite edema and the fluorescein has no late disk leakage. A lumbar puncture could be considered to exclude pseudotumor cerebri since disk edema may not always be present. The patient's short stature raises the question of other systemic diseases such as Alagille's syndrome<sup>13</sup> but he lacks posterior embryotoxon or abnormal facies. The patient does not have cutaneous manifestations of scleromyxedema.<sup>14</sup> Choroidal neovascularization and hypotony can be eliminated based on the examination. If the MRI scan, lumbar puncture, and thyroid function tests are normal, then hyperopia is the likely cause of his chorioretinal folds. Another important question relates to whether anything can be done to improve the visual acuity in the left eye with the more prominent epiretinal membrane.

The OCT shows substantial serous detachment, which could be secondary to a combination of hyperopia associated choroidal folds and distortion of the inner retina from the epiretinal membrane. The serous detachment in the left eye and visual acuity might be improved by intravitreal triamcinolone. This potential treatment should be discussed, but the serous detachment may recur when the triamcinolone is absorbed several months later. The left epiretinal membrane appears to be causing substantial macular distortion both on the red free photographs and OCT. I would suggest combining vitrectomy with epiretinal membrane removal and intravitreal triamcinolone injection since the visual acuity has deteriorated from 20/25 2 years ago to 20/100 now. I would not recommend any treatment to the much milder epiretinal membrane in the right eye.

**Editor's Note:** \_\_\_\_\_

Dr. Young presents a short 23-year-old man with decreased vision, nanophthalmos, choroidal folds, and

serous macular detachments. The differential diagnosis is provided by our consultants.

- I. Syndromes associated with nanophthalmos
  - A. Uveal effusion syndrome
  - B. Hallermann-Streiff-Francois syndrome
  - C. Oculodentodigital syndrome
  - D. Kenny-Caffey syndrome
- II. Mucopolysaccharidoses
  - A. IIA, IIB (Hunter's)
  - B. VIA, VIB (Maroteaux-Lamy)
- III. Idiopathic central serous chorioretinopathy
- IV. Vogt-Koyanagi-Harada
- V. Posterior scleritis
- VI. Alagille's syndrome
- VII. Scleromyxedema

The intriguing part of this diagnostic puzzle revolves around the patient's short stature and nanophthalmos. As Dr. Gross points out, dwarfism and nanophthalmos are components of Hallermann-Streiff syndrome, a condition in which multiple choroidal leaks have been described. The leaks and serous detachment are probably the result of choroidal effusion associated with nanophthalmos. However, this syndrome includes skin and dental abnormalities, which were denied by the patient. Kenny-Caffey syndrome is also associated with dwarfism and nanophthalmos, and radiologic evaluation of the long bones (looking for medullary stenosis of the long bone) and metabolic evaluation (assessing possibility of hypocalcemia due to hyperparathyroidism) should be conducted to confirm this diagnosis.

Drs. Lai and Shakin mention the possibility of mucopolysaccharidoses, liposomal enzyme storage disorders that may cause abnormal thickening of the sclera. Patients with these disorders have been reported to have nanophthalmos and choroidal effusions. However, this patient does not exhibit the other abnormalities associated with these enzymatic deficiency diseases. These consultants recommend a careful family history and an evaluation for these storage disorders.

Dr. Thompson concentrates on the chorioretinal folds in his analysis of this patient, pointing to the patient's hyperopia. He suggests an MRI to rule out orbital masses or thyroid disease, and thyroid function tests to look for hyperthyroidism. He also suggests consideration for lumbar puncture to exclude pseudotumor cerebri.

Therapeutically, our consultants mention the possibility of posterior sclerectomies to reduce the uveal effusion as well as vitrectomy, epiretinal membrane removal, and intravitreal triamcinolone injection (on the left eye).

#### Follow-up:

Dr. Young considered the Hallermann-Streiff syndrome but, given the absence of dental abnormalities and characteristic "beak-like" facies, rejected this diagnosis. An MRI with contrast was performed. No thickened sclera was noted and therefore no sclerectomy/sclerotomy was performed. The vision at the last examination was 20/40 in the right eye, 20/50 in the left.

#### References

1. Boynton JR, Purnell EW. Bilateral microphthalmos without microcornea associated with unusual papillomacular retinal folds and high hyperopia. *Am J Ophthalmol* 1975;79:820-826.
2. Blair NP, Brockhurst RJ, Lee W. Central serous choroidopathy in the Hallermann-Streiff syndrome. *Ann Ophthalmol* 1981;13:987-990.
3. Serrano JC, Hodgkins PR, Taylor DS, Gole GA, Kriss A. The nanophthalmic macula. *Br J Ophthalmol* 1998;82:276-279.
4. Boynton JR, Pheasant TR, Johnson BL, Levin DB, Streeten BW. Ocular findings in Kenny's syndrome. *Arch Ophthalmol* 1979;97:896-900.
5. Larsen JL, Kivlin J, Odell WD. Unusual cause of short stature. *Am J Med* 1985;78:1025-1032.
6. Brockhurst RJ. Nanophthalmos with uveal effusion: a new clinical entity. *Trans Am Ophthalmol Soc* 1974;72:371-403.
7. Vine AK. Uveal effusion in Hunter's syndrome: evidence that abnormal sclera is responsible for the uveal effusion syndrome. *Retina* 1986;6:57-60.
8. Gass JD, Jallow S. Idiopathic serous detachment of the choroid, ciliary body, and retina (uveal effusion syndrome). *Ophthalmology* 1982;89:1018-1032.
9. Atta HR, Byrne SF. The findings of standardized echography for choroidal folds. *Arch Ophthalmol* 1986;106:1234-1241.
10. Leahey AB, Brucker AJ, Wyszynski RE, Shama P. Chorioretinal folds: a comparison of unilateral and bilateral cases. *Arch Ophthalmol* 111:357-359.
11. Dailey RA, Mills RP, Stimac GK, et al. The natural history and CT appearance of acquired hyperopia with choroidal folds. *Ophthalmology* 1986;93:1336-1342.
12. Griebel SR, Kosmorsky GS. Choroidal folds associated with increased intracranial pressure. *Am J Ophthalmol* 2000;129:513-516.
13. Wells KK, Pulido JS, Judisch GF, et al. Ophthalmic features of Alagille syndrome (arteriohepatic dysplasia). *J Pediatr Ophthalmol Strabismus* 1993;30:130-135.
14. Davis ML, Barley GB, Gibson LE, Maguire LJ. Ophthalmic findings in scleromyxedema. *Ophthalmology* 1994;101:252-255.

**RETINA®**, The Journal of Retinal and Vitreous Diseases, encourages readers to submit **Diagnostic and Therapeutic Challenges** to H. Richard McDonald, MD, One Daniel Burnham Court, Suite 210C, San Francisco, CA 94109. Cases for the Diagnostic and Therapeutic Challenges section should include a detailed history of the patient, the diagnosis, the workup, the management, and finally, the question or questions that the submitter wishes to have answered by the consultants.